ARTICLE IN PRESS

The Journal of Arthroplasty xxx (2015) xxx–xxx

Contents lists available at ScienceDirect

The Journal of Arthroplasty

journal homepage: www.arthroplastyjournal.org

Variability in Distal Femoral Anatomy in Patients Undergoing Total Knee Arthroplasty: Measurements on 13,546 Computed Tomography Scans

Gokhan Meric, MD [a,b], Guilherme C. Gracitelli, MD [a,c], Luke J. Aram, BS [d,1], Michael L. Swank, MD [e], William D. Bugbee, MD [f,g]

[a] Shiley Center for Orthopaedic Research and Education, Scripps Clinic, La jolla, California
[b] Department of Orthopaedic Surgery, Balikesir University, Balıkesir Uşak yolu üzeri Çağış Yerleşkesi, Balikesir, Turkey
[c] Department of Orthopaedic Surgery, Federal University of São Paulo, Sao Paulo, Brazil
[d] DePuy Synthes, Warsaw, Indiana
[e] Christ Hospital, Cincinnati, Ohio
[f] Department of Orthopaedic Surgery, University of California, San Diego School of Medicine, La Jolla, California
[g] Department of Orthopaedic Surgery, Scripps Clinic, La Jolla, California

ARTICLE INFO

Article history:
Received 29 October 2014
Accepted 14 April 2015
Available online xxxx

Keywords:
total knee arthroplasty
distal femoral axis
distal femoral rotation
limb alignment
knee anatomy

ABSTRACT

Proper mechanical and rotational alignment plays an important role in achieving the success of the total knee arthroplasty (TKA). The purpose of the present study was to retrospectively determine with computed tomography (CT) the distal femoral valgus angle (DFVA) and femoral rotation angle (FRA). Our cohort included 13,546 CT scans of patients undergoing TKA. The average DFVA was 5.7 ± 2.3° (range from 1 to −16°) with 13.8% of patients identified as outliers. The distal FRA angle average was 3.3 ± 1.5° (range from −3 to 11°) with 2.8% of patients identified as outliers. These data can be useful in making orthopedic surgeons aware of the variability of femoral anatomy. Using the same cutting angle may lead to malposition of the femoral component.

Proper limb alignment and implant positioning are important to the success of total knee arthroplasty (TKA) [1,2]. Incorrect mechanical alignment is related to early implant wear, implant loosening and instability of the prosthesis [3,4]. Alignment within a range of ±3° varus–valgus from the mechanical axis is desired and associated with better outcomes [1,2]. Although many studies reported the benefits of proper postoperative alignment on the outcomes of TKA, some clinical studies could not correlate proper alignment with a longer implant survivorship at long-term follow-up [5,6]. Despite the controversy on this topic, the standard surgical technique of TKA should aim to maintain proper alignment.

In order to have a postoperative proper alignment, conventional knee arthroplasty instrumentation typically aligns and places implants based on the population's average anatomy. In the TKA surgical technique, with intramedullary (IM) femoral alignment guides, the distal femoral resection is typically set at 5 to 7° from the anatomic axis in order to make the resection perpendicular (0°) to the mechanical axis of the femur. This technique is based on the average angle between the anatomic and mechanical axis of the femur, which is known to be 5 to 7° [7–9]. Numerous studies have documented the use of an IM guide leads to malalignment of the femoral component of greater than 3° in up to 20% of cases [10]. Additional studies have reported considerable variations in the distal femoral valgus angle (DFVA) between patients [8,11]. In outlier patients, using same cutting angles may lead to high incidence of malalignment.

Rotational alignment of the femoral component in TKA plays an important role in achieving varus–valgus stability and patellofemoral tracking [12]. To create the appropriate femoral component rotation, the posterior condylar axis, anteroposterior axis, and transepicondylar axis have been proposed [13,14]. High variability in the femoral rotational angle (FRA) associated with all techniques has been reported [13,15,16]. With the measured resection techniques, the femoral component is typically placed 3° externally rotated to the posterior condylar line. Distal femoral anatomic abnormalities may lead to rotational malalignment when the measured resection technique is used.

Frequently, surgeons do not assess the native distal femoral anatomy preoperatively, considering the average value in the nonarthritic population. Using the standard instrumentation guides for the distal femoral resections may lead to femoral component malposition and malalignment in cases that had anatomic variability in distal femur. The purpose of this study was to determine the DFVA and FRA in a large number of patients undergoing TKA in an effort to better

One or more of the authors of this paper have disclosed potential or pertinent conflicts of interest, which may include receipt of payment, either direct or indirect, institutional support, or association with an entity in the biomedical field which may be perceived to have potential conflict of interest with this work. For full disclosure statements refer to http://dx.doi.org/10.1016/j.arth.2015.04.024.

Reprint requests: Gokhan Meric, MD, 10666 N. Torrey Pines Rd. La jolla, CA.
[1] Address: 700 Orthopaedic drive, Warsaw, USA.

http://dx.doi.org/10.1016/j.arth.2015.04.024
0883-5403/

Please cite this article as: Meric G, et al, Variability in Distal Femoral Anatomy in Patients Undergoing Total Knee Arthroplasty: Measurements on 13,546 Computed Tomography Scans, J Arthroplasty (2015), http://dx.doi.org/10.1016/j.arth.2015.04.024

understand both average femoral anatomy and the incidence of "outliers" in this arthritic population.

Material Methods

We analyzed 13,546 computed tomography (CT) scans of osteoarthritic patients undergoing TKA with patient-specific instruments using Amira visualization software (Visual Science Group, Burlington, MA, USA) and NX computer-aided design software (Siemens Corporation, Berlin, Germany). Sixty-one percent were female patients ($n = 8241$) and 39% were male ($n = 5305$). Limb alignment was identified as varus in 81% ($n = 11{,}021$) valgus in 19 % ($n = 2525$) with a range from 27 varus to 22° valgus. Average patient age was 65.4 ± 10.3.

All CT scans included the hip, knee, and ankle. Three-dimensional reconstructions were performed on each scan and key landmarks were identified in Amira and NX software. The DFVA (also termed the femoral mechanical–anatomical axis) was defined as the difference between the anatomic and mechanical axes in the coronal plane (Fig. 1). The hip center was defined as the geometric center of the femoral head as defined by a best-fit sphere. The mechanical axis was defined as the line connecting the hip center and knee center. The line connecting 2 mid-diaphyseal points defined the anatomic axis of the femur.

The angle between the posterior condylar axis and the epicondylar axis in the axial plane defined FRA (Fig. 2). The posterior condylar line was defined by two points, each on the most posterior surface of the medial and lateral condyles. The transepicondylar axis was also defined by two points, one point was on the medial epicondyle (sulcus) and one point was on the lateral epicondyle (prominence). All measurements were digitally measured using NX software.

The patient's anatomy was categorized as an outlier if femoral valgus or rotation deviated more than 3° from the measure average. All data were collected and analyzed utilizing Microsoft Excel software (Microsoft Corporation, Redmond, WA). Data were analyzed using Anova analysis.

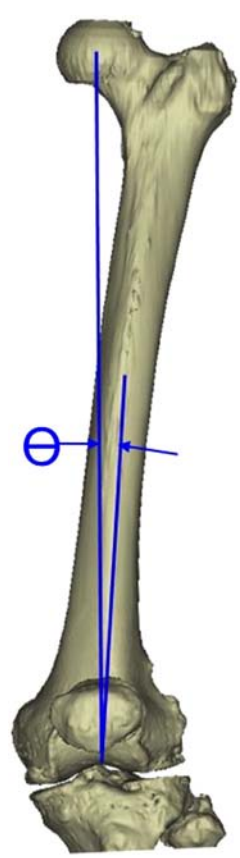

Fig. 1. Definitions of the anatomic axis, mechanical axis, and distal femoral valgus angle with the 3D reconstruction of the CT scan.

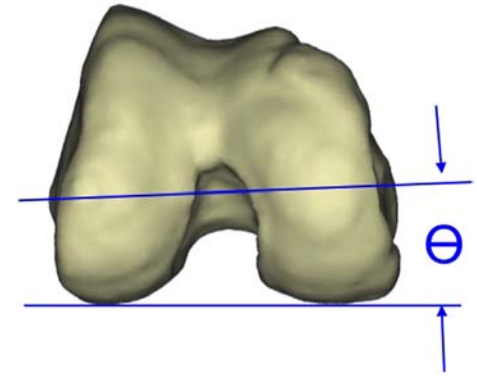

Fig. 2. The angle between the posterior condylar axis and the epicondylar axis in the axial plane define femoral rotation angle with the 3D reconstruction of the CT scan.

All engineers involved with this study were trained in the use of Amira software, NX software, and knee anatomy. CT scans, which we measured for our study, were used for the patient specific knee prosthesis. To assess reliability of the femoral mechanical axis and DFR measurements, a subsample of 11 engineers were identified to perform a repeat reading of CT scans. Engineers were blinded to the test. Six replicates were completed for 10 CT scans, for a total of 60 measures. All repeat measurements were ±0.1°, showing high reliability.

Results

The average DFVA was 5.7 ± 2.3° (range 1–16°). The average DFVA of the males was 5.82 ± 2.25° and females 5.65 ± 2.35°. The range of DFVA was 1° varus to 16° valgus (Fig. 3). Outliers in DFVA were identified in 13.8% of scans (Fig. 4).

The average distal FRA was 3.3 ± 1.5° (range 3° internal rotation to −11° external rotation) (Fig. 5). The average FRA for male patients was 3.1 ± 1.5° and the average FRA for females was 3.3 ± 1.5°. Outliers in femoral rotation were identified in 2.8% of scans (Fig. 6). All outlier data are shown in Table 1.

Discussion

This study demonstrated that the DFVA is highly variable in patients undergoing TKA. To our knowledge, this is the largest study designed to evaluate patients using modern CT scan data and accurate 3-dimensional (3D) computer modeling. CT is an excellent imaging

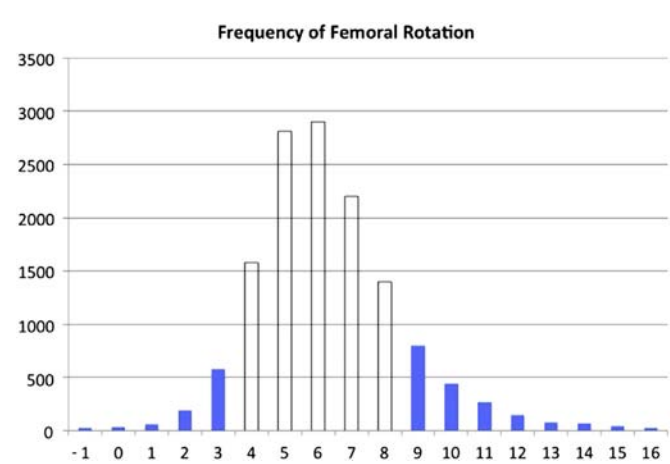

Fig. 3. The frequency of each value of distal femoral valgus angle is shown in the graphic. Outliers of the distal femoral valgus angles are shown with blue columns.

Please cite this article as: Meric G, et al, Variability in Distal Femoral Anatomy in Patients Undergoing Total Knee Arthroplasty: Measurements on 13,546 Computed Tomography Scans, J Arthroplasty (2015), http://dx.doi.org/10.1016/j.arth.2015.04.024

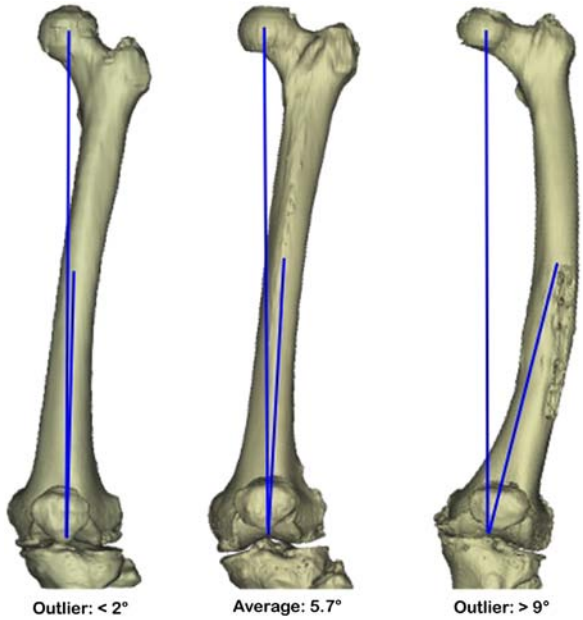

Fig. 4. Three-dimensional reconstructions of 3 femurs and definition of the distal femoral valgus angle. Left femur is an outlier with a femoral valgus angle of less than 2°. Middle femur is a typical femur with a femoral valgus angle of 5.7°. Right femur is a valgus outlier with a femoral valgus angle of greater than 9°.

modality for identifying bony landmarks and determining 3D geometry. The large sample size and accurate 3D measurements allow precise measurements of anatomic variables. We found the FRA had large angle range and the incidence of DFVA outliers to be more than 13%. Using the conventional instrumentation with the same cutting angle for the distal femoral resections may lead to femoral component malposition in patient who have anatomic variability in distal femur.

Several studies reported variability in the DFVA. Nam et al found similar variability in the relationship between distal femoral anatomic and mechanical axes in a study of 495 patients undergoing primary TKA. Utilizing hip to ankle radiographs, they showed that 28.6% of patients were outside the range of 5 ± 2° [17]. Mullaji et al studied 250 osteoarthritic limbs with full-length radiographs and found 18.8% had a femoral mechanical–anatomical axis greater than 9° [18]. Deakin et al analyzed 174 radiographs and also showed a wide distribution of femoral angles (mean 5.7°, range 2 to −9°), with males and varus knees having larger femoral mechanical–anatomical valgus angles and females and valgus knees having smaller angles [9]. These results are

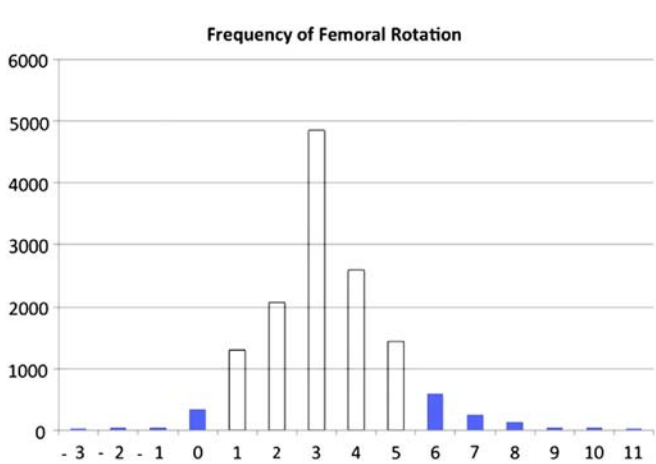

Fig. 5. The frequency of each value of femoral rotation angle is shown in the graphic. Outliers of the femoral rotation angles are shown with blue columns.

similar to our study using CT data, which determined that 13.8% of patients were ≤3° or ≥9° of distal femoral mechanical–anatomical valgus. In our study we measured sheer volume of data, which demonstrated distal femoral anatomy. Conventional instrumentation is designed according to patients' average anatomy. Using conventional instrumentation technique to achieve proper distal femoral alignment standard, a 6° valgus cut may cause malalignment during the TKA. Surgeons should be aware that in patients with anatomical variability preoperative planning is very important. Surgeons may add additional measurements such as on a long-standing radiograph to achieve proper alignment.

Many measurement methods and landmarks were identified for the FRA [12–16]. All techniques were highly variable. Arima et al showed on 30 cadavers that the range of the rotational alignment varies from 4.5° internal rotation to 15.5° external rotation [19]. Variability of the femoral rotational measurement is associated with different techniques, surgeons' experience, femur anatomy, and soft-tissue coverage of the femur epicondyles [13,19]. Many of these anatomic studies were performed with non-arthritic knees. In our study we measured DFA in arthritic knees to detect more reliable results. Posterior condylar axis with epicondylar axis technique were one of the most frequently used methods for the measured the FRA [19,20]. We used same measurement technique to measure the FRA and found 14° of variability (3°internal rotation to 11° external rotation). Conventional arthroplasty are based on 3° external rotation of the posterior femoral condyle, however this technique should include preoperative and intraoperative analysis of the FRA to avoid the femoral malrotation in cases of anatomy abnormalities of posterior condyle [21]. In our study we found that the average distal FRA was 3.3°. Using conventional 3° external rotation of the posterior femoral condyle may not result in femoral rotational malalignment and patellofemoral maltracking except in outlier patients. Preoperative planning is important to achieve proper alignment. Surgeons should be aware anatomical variability of the femur and additional measurements such as on a long standing radiograph should be measured.

In outlier patients, femoral rotational variability may cause instability, tibiofemoral kinematic problems, patellofemoral maltracking, dislocation, and instability [15,22,23]. Berger et al reported that 3 to 8° internal rotation of femoral component correlated with patellar dislocation, 7 to 17° internal rotation correlated with early patellar dislocation, late term patellar prosthesis failure and increased incidence of lateral retinacular release [5,12]. Also malrotation rotation of the femoral component can lead to flexion and extension gap differences and flexion instability. This flexion instability can cause pain of the medial tibial metaphysis and discomfort during the knee flexion [24].

The relationship of component alignment to TKA clinical outcome has been reported in the literature. The distal femoral anatomy is highly variable in the population of patients undergoing TKA. Using the same cutting angle for the distal femoral resection may lead to femoral component malposition. Several studies reported a strong relationship between the proper implant alignment and position and the stability and lower rate of implant loosening. Ritter et al reported a significant correlation between varus or valgus malalignment of the TKA and the prosthesis failure in a study of 6070 patients [25]. Fang et al reported that poor anatomic alignment of the TKA was associated with a 6.9 times greater risk of implant failure [26]. Sharkey et al reported 212 revision TKAs where more than half of the patients who had revision surgeries presented with instability, malalignment or malposition, and failure of the fixation [27]. However some studies could find no relationship between alignment and implant survivorship. Parratte et al reported 398 TKA with 15 years follow-up. One Hundred six knees were outliners (mechanical axis of beyond 0 ± 3°). No correlation between mechanical alignments and implant survivorship at 15 years was found. They concluded that mechanical axis of 0 ± 3° did not improve the implant survival in long-term follow-up [6].

This study was not designed to look at outcome-related alignment but rather to define the anatomy patients present at the time of TKA. Another consideration of this study was that we performed the

Please cite this article as: Meric G, et al, Variability in Distal Femoral Anatomy in Patients Undergoing Total Knee Arthroplasty: Measurements on 13,546 Computed Tomography Scans, J Arthroplasty (2015), http://dx.doi.org/10.1016/j.arth.2015.04.024

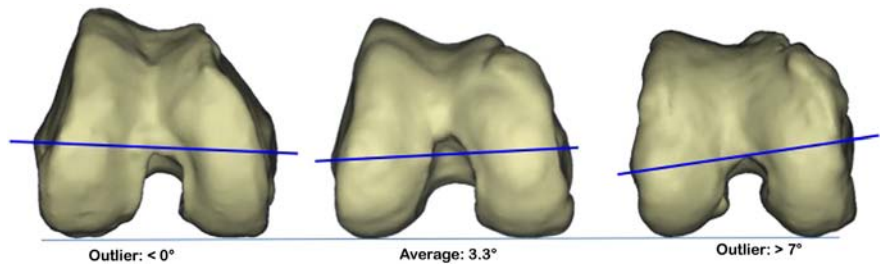

Fig. 6. Three-dimensional reconstructions of three femurs and definition of the femoral rotation angles are shown. Left femur is an outlier with a femoral rotation angle of less than 0°. Middle femur is a typical femur with a femoral rotation angle of 3.2°. Right femur is an outlier with a femoral rotation angle of greater than 6°.

Table 1
Number of Patients Outside the Average ±3° for Femur Rotational Angle and Distal Femoral Valgus Angle.

	Female *N*[a] and %	Male *n*[a] and %	Total *N*[a] and %
FRA[b]			
Less than 0°	16 (0.2%)	13 (0.2%)	29 (0.2%)
More than 6°	231 (2.8%)	122 (2.3%)	353 (2.6%)
DFVA[c]			
Less than 4°	602 (7.3%)	306 (5.8%)	908 (6.7%)
More than 9°	590 (7.1%)	382 (7.2%)	972 (7.2%)

[a] *n* number of patients.
[b] FRA femur rotational angle.
[c] DFVA distal femoral valgus angle.

measurements in osteoarthritic knees and our findings might not represent normal knee anatomy. However our findings in the knees with osteoarthritis are useful information to guide surgeons during TKA surgeries.

The anatomic information gained from this large number of patients should be useful in confirming the high variability of these measurements seen in other studies and alert surgeons that routine use of guides without adequate measurement of the anatomic and mechanical axes of the distal femur can result in distal femoral resections in those that are not perpendicular to the mechanical axis. These findings suggest that routine use of conventional instruments and average distal femoral valgus angular resections can lead to deviation from neutral mechanical alignment of the femoral component in a significant number of outliers' and result in mechanical limb malalignment. Also using traditional instrumentation that reference the femur posterior condyle without adequate corrections may lead to wrong rotation of the femoral implant in the outlier patient population [28].

Conclusions

Proper mechanical axis and rotational alignment are desirable goals during TKA. The present study was done with a large number of patients with knee arthritis, who undergo TKA. These data can be useful in making orthopedic surgeons aware of the variability of femoral anatomy in the arthritic knee. Using the same cutting angle may lead to malposition of the femoral component and mechanical limb malalignment with a significant number of outliers. Surgeons should be aware of the variability of the distal femur in patients undergoing TKA and perform additional measurements preoperatively to achieve proper alignment. To improve accuracy in TKA, current and future techniques and instrumentation should consider technical adjustments.

References

1. Bargren JH, Blaha JD, Freeman MA. Alignment in total knee arthroplasty. Correlated biomechanical and clinical observations. Clin Orthop Relat Res 1983(173):178.
2. Choong PF, Dowsey MM, Stoney JD. Does accurate anatomical alignment result in better function and quality of life? Comparing conventional and computer-assisted total knee arthroplasty. J Arthroplast 2009;24(4):560.
3. Insall JN, Binazzi R, Soudry M, et al. Total knee arthroplasty. Clin Orthop Relat Res 1985(192):13.
4. Bathis H, Perlick L, Tingart M, et al. Alignment in total knee arthroplasty. A comparison of computer-assisted surgery with the conventional technique. J Bone Joint Surg Br 2004;86(5):682.
5. Jeffery RS, Morris RW, Denham RA. Coronal alignment after total knee replacement. J Bone Joint Surg Br 1991;73(5):709.
6. Parratte S, Pagnano MW, Trousdale RT, et al. Effect of postoperative mechanical axis alignment on the fifteen-year survival of modern, cemented total knee replacements. J Bone Joint Surg 2010;92(12):2143.
7. Wang Y, Zeng Y, Dai K, et al. Normal lower-extremity alignment parameters in healthy Southern Chinese adults as a guide in total knee arthroplasty. J Arthroplast 2010;25(4):563.
8. Tang WM, Zhu YH, Chiu KY. Axial alignment of the lower extremity in Chinese adults. J Bone Joint Surg 2000;82-A(11):1603.
9. Deakin AH, Basanagoudar PL, Nunag P, et al. Natural distribution of the femoral mechanical-anatomical angle in an osteoarthritic population and its relevance to total knee arthroplasty. Knee 2011;19(2):120.
10. Cates HE, Ritter MA, Keating EM, et al. Intramedullary versus extramedullary femoral alignment systems in total knee replacement. Clin Orthop Relat Res 1993(286):32.
11. Lasam MP, Lee KJ, Chang CB, et al. Femoral lateral bowing and varus condylar orientation are prevalent and affect axial alignment of TKA in Koreans. Clin Orthop Relat Res 2013;471(5):1472.
12. Berger RA, Rubash HE, Seel MJ, et al. Determining the rotational alignment of the femoral component in total knee arthroplasty using the epicondylar axis. Clin Orthop Relat Res 1993(286):40.
13. Siston RA, Patel JJ, Goodman SB, et al. The variability of femoral rotational alignment in total knee arthroplasty. J Bone Joint Surg 2005;87(10):2276.
14. Yau WP, Chiu KY, Tang WM. How precise is the determination of rotational alignment of the femoral prosthesis in total knee arthroplasty: an in vivo study. J Arthroplast 2007;22(7):1042.
15. Miller MC, Berger RA, Petrella AJ, et al. Optimizing femoral component rotation in total knee arthroplasty. Clin Orthop Relat Res 2001(392):38.
16. Whiteside LA, McCarthy DS. Laboratory evaluation of alignment and kinematics in a unicompartmental knee arthroplasty inserted with intramedullary instrumentation. Clin Orthop Relat Res 1992(274):238.
17. Nam D, Maher PA, Robles A, et al. Variability in the relationship between the distal femoral mechanical and anatomical axes in patients undergoing primary total knee arthroplasty. J Arthroplast 2013;28(5):798.
18. Mullaji AB, Marawar SV, Mittal V. A comparison of coronal plane axial femoral relationships in Asian patients with varus osteoarthritic knees and healthy knees. J Arthroplast 2009;24(6):861.
19. Arima J, Whiteside LA, McCarthy DS, et al. Femoral rotational alignment, based on the anteroposterior axis, in total knee arthroplasty in a valgus knee. A technical note. J Bone Joint Surg 1995;77(9):1331.
20. Siston RA, Cromie MJ, Gold GE, et al. Averaging different alignment axes improves femoral rotational alignment in computer-navigated total knee arthroplasty. J Bone Joint Surg 2008;90(10):2098.
21. Ranawat AS, Ranawat CS, Elkus M, et al. Total knee arthroplasty for severe valgus deformity. J Bone Joint Surg 2005;87(Suppl. 1(Pt 2)):271.
22. Fehring TK. Rotational malalignment of the femoral component in total knee arthroplasty. Clin Orthop Relat Res 2000(380):72.
23. Singerman R, Pagan HD, Peyser AB, et al. Effect of femoral component rotation and patellar design on patellar forces. Clin Orthop Relat Res 1997(334):345.
24. Stahelin T, Kessler O, Pfirrmann C, et al. Fluoroscopically assisted stress radiography for varus–valgus stability assessment in flexion after total knee arthroplasty. J Arthroplast 2003;18(4):513.
25. Ritter MA, Davis KE, Meding JB, et al. The effect of alignment and BMI on failure of total knee replacement. J Bone Joint Surg 2011;93(17):1588.
26. Fang D, Ritter MA. Malalignment: forewarned is forearmed. Orthopedics 2009;32(9). http://dx.doi.org/10.3928/01477447-20090728-29.
27. Sharkey PF, Hozack WJ, Rothman RH, et al. Insall Award paper. Why are total knee arthroplasties failing today? Clin Orthop Relat Res 2002(404):7.
28. Bugbee WD, Mizu-Uchi H, Patil S, et al. Accuracy of implant placement utilizing customized patient instrumentation in total knee arthroplasty. Adv Orthop 2013; 2013:891210.

Please cite this article as: Meric G, et al, Variability in Distal Femoral Anatomy in Patients Undergoing Total Knee Arthroplasty: Measurements on 13,546 Computed Tomography Scans, J Arthroplasty (2015), http://dx.doi.org/10.1016/j.arth.2015.04.024