American Journal of Emergency Medicine 31 (2013) 1605–1611

Contents lists available at ScienceDirect

American Journal of Emergency Medicine

journal homepage: www.elsevier.com/locate/ajem

Review

Review of techniques for the removal of trapped rings on fingers with a proposed new algorithm ☆

Asim Kalkan, MD [a,*], Ozkan Kose, MD [b], Mahmut Tas, MD [c], Gokhan Meric, MD [d]

[a] Department of Emergency Medicine, Faculty of Medicine, Recep Tayyip Erdogan University, Rize 53020, Turkey
[b] Department of Orthopaedics and Traumatology, Antalya Education and Research Hospital, Antalya, Turkey
[c] Department of Emergency Medicine, Diyarbakır Education and Research Hospital, Diyarbakır, Turkey
[d] Department of Orthopaedics and Traumatology, Faculty of Medicine, Balikesir University, Balikesir, Turkey

ARTICLE INFO

Article history:
Received 22 April 2013
Received in revised form 16 June 2013
Accepted 17 June 2013

ABSTRACT

Various removal techniques for rings trapped on the finger have been described in the current literature. However, despite this being a frequently encountered situation in emergency departments, there is no comprehensive algorithm to manage and follow these patients in the current literature. The purposes of this study were to describe the most commonly used ring removal techniques and to establish an algorithm for the removal of rings trapped on fingers. We performed a comprehensive literature search in several databases to identify all articles, case reports, letters, and book chapters that focus on ring removal techniques in English language from 1960 to the present. There are 2 methods of removal: (1) noncutting techniques in which the rings can be removed without breaking the integrity of the ring and (2) various ring-cutting equipments and tools. All these techniques are classified into distinct groups and described in detail with illustrations. Furthermore, an algorithm for handling such patients is established according to case-based patient care. Following an algorithm for the removal of trapped rings on the finger will be useful for patients and emergency physicians. It will also prevent possible complications and will save time.

1. Introduction

Although rings are generally harmless pieces of jewelry in daily life, they can present with severe medical problems. The number of patients presenting to emergency departments (EDs) with rings trapped on fingers is by no means negligible. Trapped ring trauma may develop in association with infection, skin disorders, allergic reactions, bee sting, and pregnancy or may simply be caused by tightness of the ring itself. A trapped ring may cause nerve damage, ischemia, and even gangrene in the distal part of the finger in case of delayed removal [1]. Therefore, it is important to remove the stuck rings as early as possible. Patients often try to remove their stuck rings several times before presentation to ED. Thus, it is generally difficult to remove a ring from a painful and swollen finger.

Various removal techniques have been described in the current literature. However, despite this being a frequently encountered situation in EDs, there is no algorithm for emergency physicians to manage and follow up these patients. Emergency medicine textbooks do not even contain a comprehensive advice on the subject [2–4]. The purposes of this article were to describe the most commonly used ring removal techniques and to establish an algorithm for the removal of rings trapped on fingers.

2. Materials and methods

PubMed, Clinical Key/Elsevier, EBSCO Discovery Service, MD Consult Science Direct, Scopus, EMBASE, Medscape, and Google Scholar electronic databases were used for the literature search in English language. The following terms were adopted for each database search: “ring,” “removal,” “stuck,” “ring removal,” and “ring removal technique.” Publications in languages other than English were excluded. Thirty-seven texts published as case reports and letters to editors, 4 book chapters, and 1 compilation were found. The texts were all examined in detail, and ring removal techniques from 1960 to the present were evaluated.

3. Results

Although several authors claimed that they described novel techniques, all these techniques share similar features and steps. Basically, there are 2 methods of removal: (1) noncutting techniques in which the rings can be removed without breaking the integrity of the ring and (2) various ring-cutting equipments and tools. There are several noncutting techniques for the removal of a stuck ring; however, most of these techniques are just a modification of a

☆ Contributorship statement: Asim Kalkan and Ozkan Kose were responsible for the original idea and literature review. Mahmut Tas and Gokhan Meric provided advice on content and style. All authors contributed to the collection, analysis, and interpretation of data and made the revisions and contributed to the intellectual concept of this review article.

* Corresponding author. Tel.: +90 464 217 0366; fax: +90 464 217 0367.
E-mail address: drasimkalkan@hotmail.com (A. Kalkan).

0735-6757/$ – see front matter © 2013 Elsevier Inc. All rights reserved.
http://dx.doi.org/10.1016/j.ajem.2013.06.009

previously described technique. Noncutting techniques can be classified into 5 distinct groups:

1. Winding technique
2. Compression technique
3. Caterpillar technique
4. Twin thread technique
5. Glove technique

Herein, these techniques together with preparatory procedures before removal and the equipment are described in sequence.

3.1. Pretreatment and equipment

Before attempting to remove a stuck ring, sufficient pain control should be provided. Digital block or local anesthetic creams can be used for this purpose. Digital block should be avoided if ischemia findings are present in the finger or in the presence of wounds or fractures [5]. Furthermore, epinephrine-free local anesthetics should be chosen because ischemia may be aggravated with vasoconstrictive effect of the epinephrine. Most children or elderly people may not be compliant because of pain and anxiety. Because some of these techniques require full compliance of the patient, it may be useful to provide sedoanalgesia with fentanyl (1-1.5 μg/kg) or midazolam (0.05 mg/kg) in adults and ketamine (1 mg/kg intramuscularly) in children [6,7]. Elevating the arm while applying an ice pack for 10 to 15 minutes before the procedure will be helpful to reduce edema. Inflating a blood pressure cuff around the arm before dropping off the arm will prevent the redevelopment of edema and increase the success rate [8]. If there is an open wound on the finger, this should be cleaned and washed with saline solution, and any foreign bodies should be removed. The skin should also be cleaned with povidone iodine [9]. Tetanus prophylaxis in patients with open wounds should be performed according to the vaccination history of the patient [10,11]. A single dose of intravenous antibiotics can be administered in contaminated wounds.

3.2. Necessary equipments

Necessary equipments are listed as follows:

1. Water-soluble lubricator (various antibiotic creams, pomades, and glycerin can also be used)
2. No: 0 suture thread or dental floss
3. Surgical glove (a powder-free glove is recommended in the presence open wounds)
4. Rubber band (the finger of a surgical glove can also be used instead of rubber band)
5. Penrose drain
6. Elastic tourniquet
7. Blood pressure cuff
8. Local anesthetics for digital block
9. Manual ring cutters
10. Electric saws (Dremel motor saw, dental saw, dental drill, etc)
11. Pliers

4. Technique 1: winding technique

In this technique, a piece of thread and lubricator are required. Instead of a piece of thread, a surgical suture, or a nylon tape, as well as a rubber band, can be wrapped around the finger [12–15]. First, the thread is passed under the ring. Next, the finger is tightly wrapped from proximal to distal direction, and compression should always pass the proximal interphalangeal (PIP) joint. Then, pull the proximal end of the thread toward the tip of finger. The thread will start unwind as you pull it and push the ring toward the tip; gradually, the ring will slide over the compressed finger (Fig. 1). Several authors modified this technique by using different materials to wrap the finger, but the basic principle of the removal mechanism is the same in all of these techniques [16–18].

5. Technique 2: compression technique

In this technique, 2 penrose drains are needed. The principle of this technique is reducing the edema in distal part of finger and blocking the blood flow to congest the finger again. First penrose drain is tightly wrapped around the finger like a tourniquet just distal to the ring and PIP joint and secured in place with the help of a surgical clamp. Second penrose drain is a wound around the finger from the first penrose drain toward the incarcerated ring to compress the edema. While the first penrose drain (tourniquet) is in place, remove the second penrose drain and move the ring over the finger (Fig. 2) [19–24]. Actually, winding techniques and compression techniques seem similar; however, in compression techniques, the wrapped bands do not pass under the ring. This procedure can be repeated several times until the swelling is reduced sufficiently to remove the ring.

6. Technique 3: the caterpillar technique

Only a lubricator is required in this technique. Initially, the finger should be thoroughly lubricated. Caterpillar technique involves a sequential of movements to propel the ring toward to the tip of finger. The back of the hand is held parallel to the ground, while upward pressure is applied from beneath swing the top portion of the ring forward. Then, press downward on the ring and swing the bottom portion of the ring toward the finger tip. The ring will slide over the finger with the repetition of these movements (Fig. 3). There may be resistance and pain while the ring is passing the level of PIP joint. St Laurent [25] claimed that she has been using the caterpillar technique for more than 10 years with remarkable success. Because this

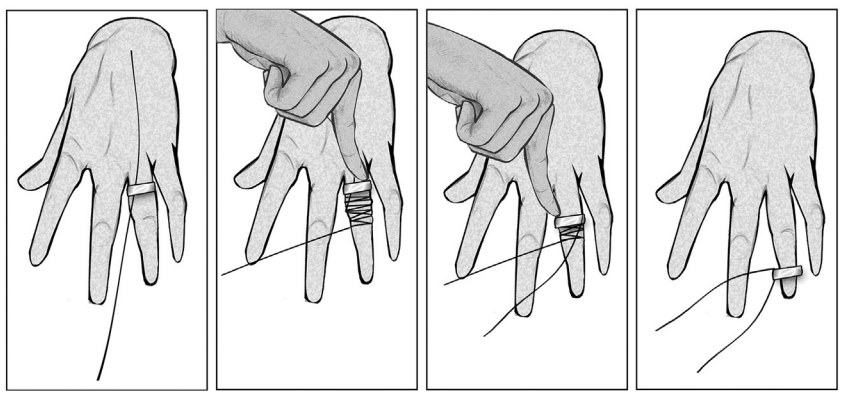

Fig. 1. Winding technique.

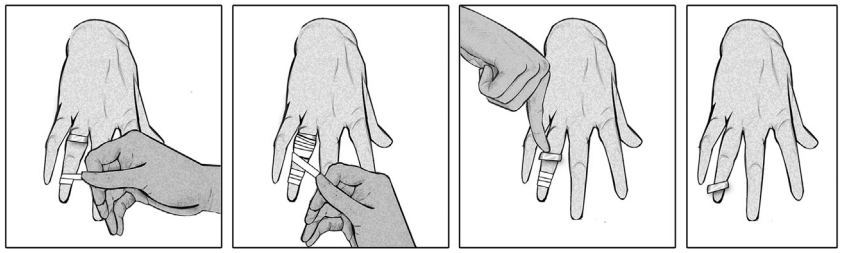

Fig. 2. Compression technique.

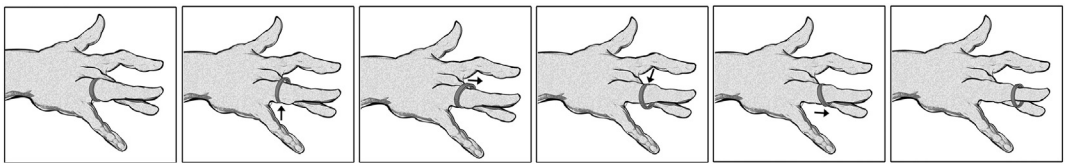

Fig. 3. The caterpillar technique.

technique do not necessitate any special equipment or device, it is very practical; however, it is not suitable for elderly patients with arthritis and prominent PIP joint.

7. Technique 4: the twin threads technique

Two threads and a lubricant are required in this technique. Any thin and strong thread will work fine; however, surgical sutures can also be used because they are available in most ED. Threads are attached to the ring on the opposite sides. The finger is well lubricated first. The threads must be parallel to the finger and to each other. An assistant takes the threads continuously toward the tip of finger and puts a moderate amount of tension on the threads. The physician holds the ring with the thumb and index fingers from dorsal and volar aspects. First, a controlled outward pressure is applied to the ring on the volar aspect with the thumb; once the ring slowly advanced, the index finger applies the outward pressure. Continuous tension on the threads will prevent the ring to turn back to its place, and the ring will gradually move toward the tip of finger with these alternating movements (Fig. 4). Burbridge and Ritter [26] and Chandra et al [27] reported that the twin threads technique can be useful if the ring is not desired to be cut off. The most important trick of this technique is the impatience between the alternating movements, and let the ring advancement before performing the second action. This technique will not be successful in patients with excessively swollen fingers, an open wound, or finger fractures.

8. Technique 5: the glove technique

A surgical glove and a lubricant are needed in this technique. One of the fingers of a surgical glove is cut from the base and the tip to obtain a cylindrical tube. This cylindrical tube is then passed beneath the ring with the help of a small surgical forceps. The segment of the rubber beyond the ring turned inside out and is pulled toward the finger tip to slide the ring over the glove (Fig. 5). Inoue et al [28] reported that the glove technique can be useful if the thread winding technique has failed. Furthermore, they claimed that this technique can be applied to burned, wounded, fractured, and inflamed fingers. However, it is difficult to pass the glove beneath the ring on a very swollen finger. In our opinion, this technique is not practical even if a lubricant is used because of the narrow space between the ring and the finger.

9. Ring cutters

Several authors suggest using ring cutters when the above-mentioned noncutting techniques have failed. Various types of cutters have been used in the literature such as manual ring cutters, pliers, pincers, the Dremel motor saw, dental saws, diamond-tipped saws, and even a dental drill. Ring cutter should be chosen particularly in patients with open wounds or fractures in the fingers or those with arthritic fingers. Thermal injuries caused by heating of the ring during the cutting process or superficial injuries cause by the device have been reported as complications of the ring cutters.

9.1. Manual ring cutters

Manual ring cutters are special tools designed for cutting rings. These tools are available in many EDs. The tool's safety lever is passed beneath the ring to protect the finger from the sharp serrated saw and cutting takes places over the top. One hand holds the handle, and the other hand twists the large thumbscrew to cut through the ring

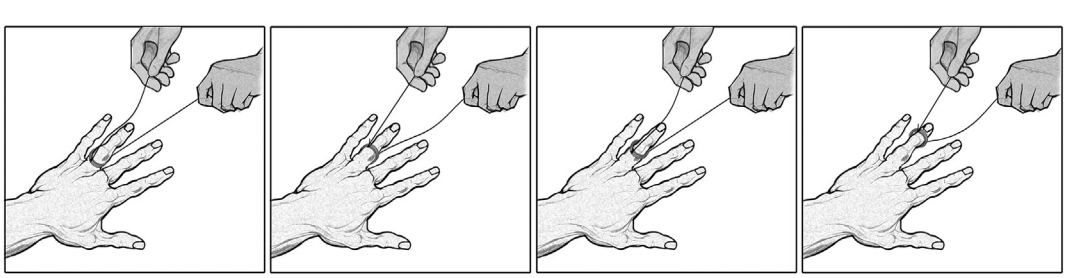

Fig. 4. The twin threads technique.

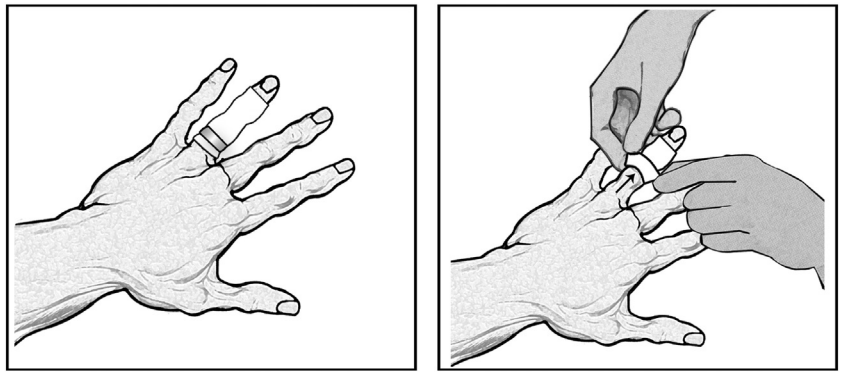

Fig. 5. The glove technique.

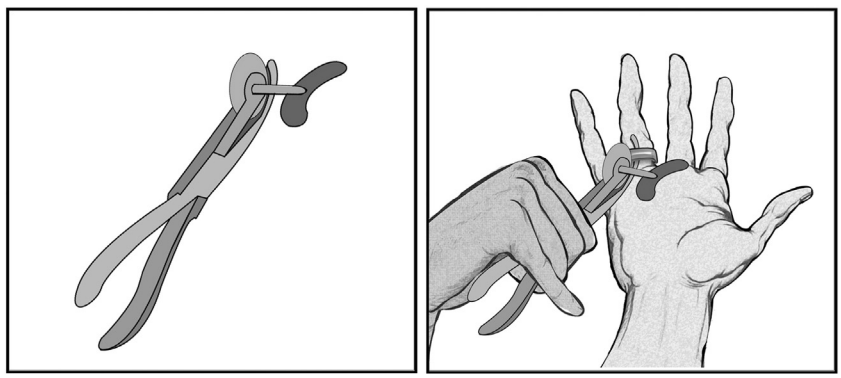

Fig. 6. Manual ring cutters.

(Fig. 6). Because the toothed parts of these saws are not very hard and cutting depends on hand power, they can only cut rings made of soft materials such as gold, silver, copper, or plastic [29]. It is not proper to cut rings made of steel, tungsten carbide, or titanium, which are extremely hard materials. The serrated saw may be damaged during cutting such hard materials. However, Kapickis and Kutz [30] reported that nonmetallic titanium rings can also be cut with these simple manual ring cutters in the ED in 10 to 15 minutes. They recommended using manual ring cutters for titanium rings, too. Because electric saws are more expensive and are not always available in ED, spending more time and effort may be the only choice.

There are also pliers generally made of steel used in many EDs that can cut rings. We could not identify any report regarding the use of pliers in the current literature. However, they are very practical and effective for cutting rings, which is made of soft metals (Fig. 7). Pincers are also useful for the removal of rings made of ceramic and tungsten carbide materials [31]. Tungsten carbide contains the inorganic chemical component (tungsten and carbon), which makes it extremely hard. However, when pressure is applied with pincers, it shatters like glass. Controlled pressure should be applied in removing a trapped ring from the finger with pincers to avoid injuring the finger; thus, adjustable pincers are more suitable for this purpose (Fig. 8).

9.2. Electric hand saws

Rings made of steel, tungsten carbide, or titanium, which has recently become popular, cannot be cut with simple manual cutters. Electric saws, Dremel motor saws, diamond-tipped saws, dental saws, or dental drills can be used for these types of rings. There is effectively little difference between these saws. The dental drill used for root canal work has a long, thin tip with a diamond at the end parallel to the working arm and that revolves at 15 000 rpm. Ricks [32] reported

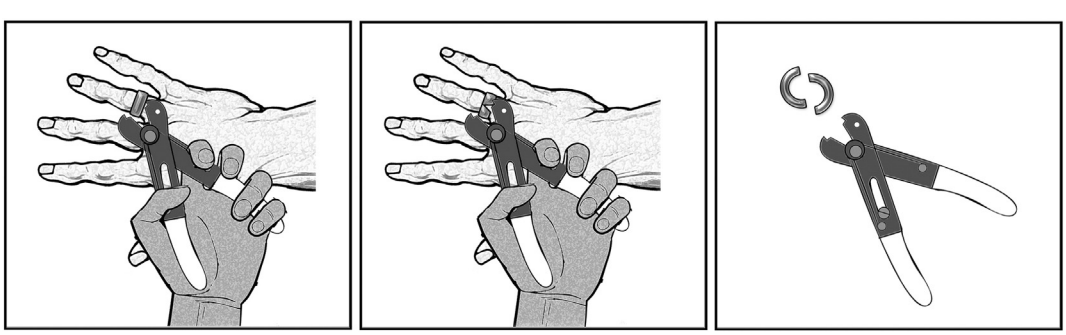

Fig. 7. Plier.

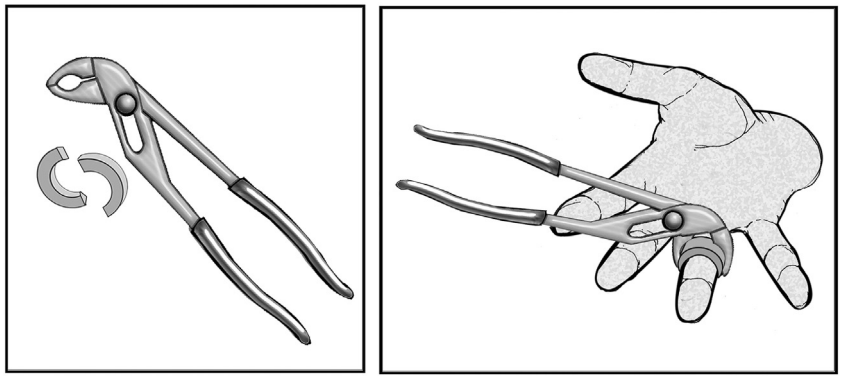

Fig. 8. Pincer.

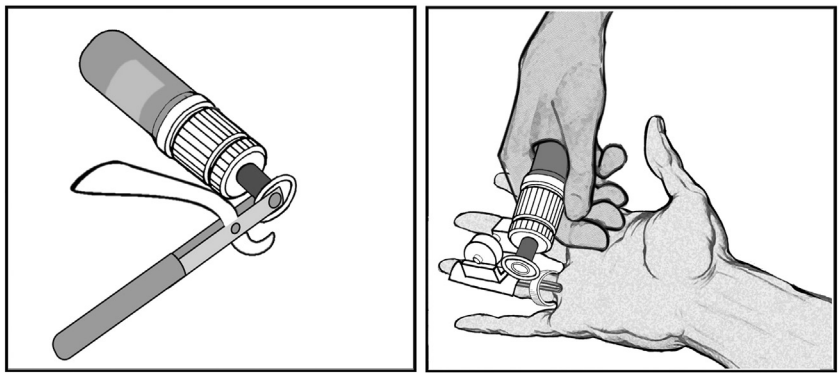

Fig. 9. Electric hand saws.

cutting a ring made from tungsten carbide in approximately 15 minutes using a dental drill. Several authors have cut rings, particularly those made of hard materials, using the Dremel motor saw [33–37] (Fig. 9). Other authors have used diamond-tipped drills, which resemble the Dremel motor saw and share the same mechanism [38–42]. Taylor and Boyd [43] and Chambers and Harper [44] reported cutting rings made from titanium and a hard metal using the dental saws used by dentists to cut teeth. The only difference between dental saws and diamond-tipped saws is their size. Sazwan et al [45] also cut and removed rings using a dental drill used by dentists for fillings similar to Ricks [32]. The finger must constantly be kept wet to protect against friction-associated heat and burns while cutting rings with electric saws. This can be achieved with intermittent instillation of water with the help of a serum set (Fig. 10).

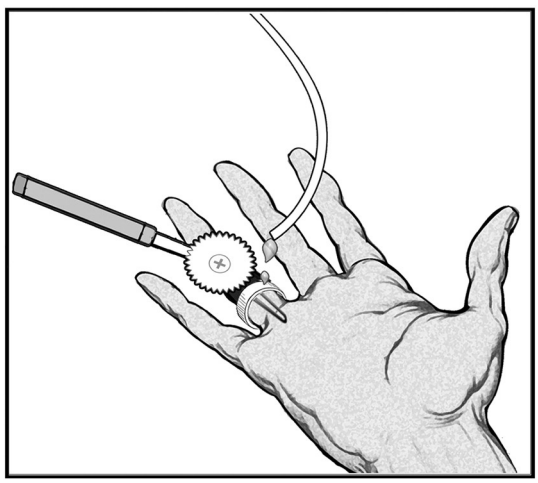

Fig. 10. Intermittent instillation of water with the help of a serum set.

10. Discussion

Although several noncutting techniques and various ring cutters have been described and used, there is no established algorithm to manage these patients in the ED in the current literature. The knowledge about this issue is scattered in a huge number of articles and needed to be synthesized in the form of an algorithm. A stuck ring may present in a variety of clinical presentation, and not all rings and patients are similar. Therefore, it is important how to handle different cases and conditions. We proposed a new practical algorithm for the removal of stuck rings (Fig. 11).

Initially, the finger should be evaluated carefully before attempting to remove a stuck ring. The first thing to look for is the presence of edema and ischemia. Shooting pain, prolonged capillary refill time (>2-3 seconds), cyanosis, and inability to perform 2-point discrimination indicate ischemia. If findings of ischemia are present, the ring must be removed urgently to prevent any permanent damage to the extremity. Ring-cutting techniques should be used first. In patients with no ischemia findings, the presence of fracture in the finger, arthritis, or open wound should be investigated in the second stage. The ring-cutting option should be taken in patients with fractures, open wounds, or advanced arthritis because noncutting techniques may further damage an already injured finger. A prominent enlargement of PIP joint caused by arthritis, particularly in elderly patients, significantly decreases the success rate of noncutting techniques.

In patients with no findings of ischemia, excessive swelling, fracture, open wound, or arthritis, noncutting techniques can be used

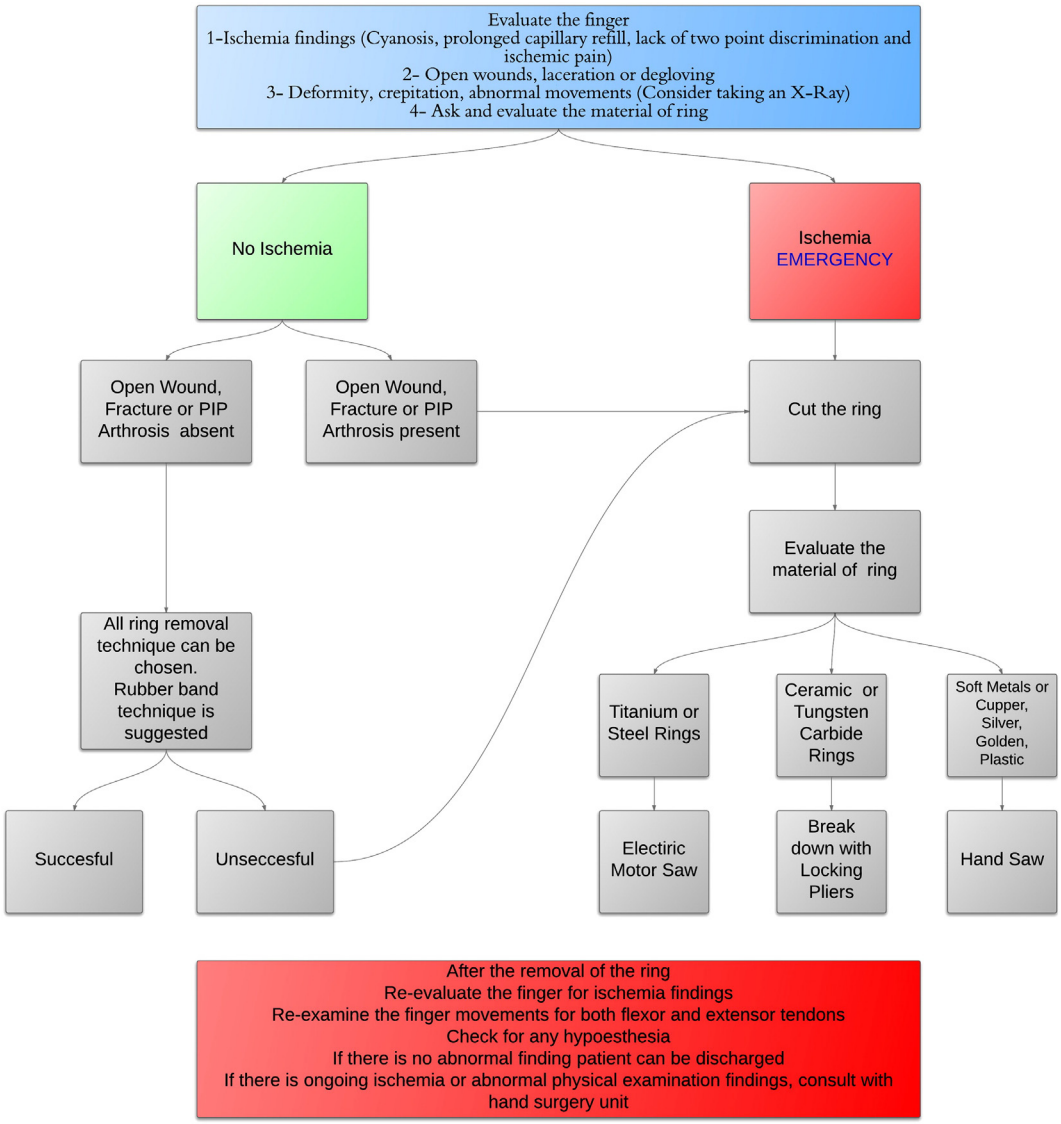

Fig. 11. Algorithm of removal of rings.

safely because enough time is present before the formation of ischemia. However, because the lymphatic and venous drainage is hindered, ischemia may develop soon in time. Therefore, a fast intervention is feasible. All noncutting techniques can be used. In case of failure, same technique can be tried 2 or 3 times, or another technique can be used. Patients should be informed about the details of the procedure and chance of failure. This will reduce anxiety and maintain the compliance of the patient.

If noncutting techniques are unsuccessful, then the ring should be cut off. Before starting to cut the ring, the material the ring is made of must be evaluated and questioned because cutting technique is planned according the material of the ring. It is easier to break rings made from ceramic or tungsten carbide than to cut them off. A ceramic or tungsten carbide ring will break under controlled pressure using locking pliers. It is easier to cut rings made from soft materials such as copper, gold, silver, or plastic. Simple ring cutters or pointed pliers found in EDs can be used for this purpose. Electric motor hand saws must be used on rings made of hard materials such as titanium or steel. Excessive heat can be produced with high-speed cutters that may lead to thermal burns. Keeping the finger and the ring wet will avoid this complication. Fire department assistance can be sought in the case of rings that cannot be cut off using electric hand saws.

Once trapped rings have been removed, the finger should be examined once again; particularly, circulation must be checked carefully. Tetanus prophylaxis and antibiotherapy must not be overlooked in the presence of cuts or trauma-associated contaminated wounds. If a circulatory problem is identified in the finger after ring removal, the hand surgery department should be consulted. No matter how the ring is removed, soft tissues and tendon examination must be performed afterward, together with monitoring for ischemia. Patients with no findings of ischemia, normal sensorimotor examinations, and reduced edema can be discharged safely [46]. Use of this algorithm by emergency physicians will ensure patient comfort and avoid loss of time and unnecessary expenditure of effort.

References

[1] Lim BH, Tan BK, Peng YP. Digital replantations including fingertip and ring avulsion. Hand Clin 2001;17:419–31.
[2] Buttaravoli P. Minor emergencies. Chapter 152. 3rd ed. page 604.
[3] Tintinalli JE. Emergency medicine: a comprehensive study guide. Ring tourniquet syndrome. 6th ed. page 312.
[4] Pfenninger John L. Pfenninger and Fowler's procedures for primary care: expert consult. Ring removal from an edematous finger. Chapter 31. 3rd Ed.; 2010.
[5] Fuchs SM. Ring removal. In: King C, Henretig FM, editors. Textbook of pediatric emergency procedures. 2nd ed. Philadelphia: Lippincott Williams & Wilkins; 2008.

[6] Bawden J, Villa-Roel C, Singh M, Fabris G, Bond K, Boyko D, et al. Procedural sedation and analgesia in a Canadian ED: a time-in-motion study. Am J Emerg Med 2011;29:1083–8.
[7] Bahn EL, Holt KR. Procedural sedation and analgesia: a review and new concepts. Emerg Med Clin North Am 2005;23:503–17.
[8] Venters WB. Ring removal from a swollen finger: a refined technique. J Surg Orthop Adv 2006;15:181–3.
[9] Uygur F, Özyurt M, Evinç R, Hosbul T, Çeliköz B, Haznedaroglu T. Comparison of octenidine dihydrochloride (Octenisept®), polihexanide (Prontosan®) and povidon iodine (Betadine®) for topical antibacterial effects in *Pseudomonas aeruginosa*–contaminated, full-skin thickness burn wounds in rats. Central European Journal of Medicine 2008;3:417–21.
[10] Advisory Committee on Immunization Practices. Recommended adult immunization schedule: United States, 2012. Ann Intern Med 2012;156:211.
[11] Wound management and tetanus prophylaxis. http://www.uptodate.com/contents/image?imageKey=PEDS%2F61087&topicKey=EM%2F6332&source=see_link.
[12] Witz R. Ring removal. Nurse Pract 2002;27:54.
[13] Barnett RC. In: Roberts JR, Hedges JR, editors. Soft tissue foreign body removal. Clinical procedure in emergency medicine. Philadelphia: WB Saunders; 1993. p. 588–90.
[14] Mizrai S, Lunski I. A simplified method for ring removal from an edematous finger. Am J Surg 1986;151:412–3.
[15] Manca D. Practice tips. Ring and string. Can Fam Physician 1997;43:859.
[16] Thilagarajah M. An improved method of ring removal. J Hand Surg [Br] 1999;24:118–9.
[17] McElfresh EC, Peterson-Elijah RC. Removal of a tight ring by the rubber band. J Hand Surg [Br] 1991;16:225–6.
[18] Hiew LY, Juma A. A novel method of ring removal from a swollen finger. Br J Plast Surg 2000;53:173–4.
[19] Chiu TF, Chu SJ, Chen SG, Chen SL, Chen TM. Use of a Penrose drain to remove an entrapped ring from a finger under emergent conditions. Am J Emerg Med 2007;25:722–3.
[20] Kates SL. A novel method of ring removal from the aging finger. Geriatric Orthopaedic Surgery & Rehabilitation 2010:1;78–79.
[21] Cresap CR. Removal of a hardened steel ring from an extremely swollen finger. Am J Emerg Med 1995;13:318–20.
[22] Nancarrow JD. A simple technique for removing stubborn rings prior to hand surgery. J Hand Surg 1993;18:544.
[23] Shah A, Asirvatham A, Ellis RD. An improved technique for creating a digital tourniquet. Orthopaedic Rev 1992;11:91–2.
[24] Clarke AC, Spencer RF. Ring removal from the injured or swollen finger. J R Coll Surg Edinb 1991;36:59.
[25] St Laurent C. The caterpillar technique for removal of a tight ring. Anesth Analg 2006;103:1060–1.
[26] Burbridge MT, Ritter SE. An alternative method to remove a ring from an edematous finger. Am J Emerg Med 2009;27:1165–6.
[27] Chandra A, Muchedzi T. Ujuzi: ring removal: a critical emergency procedure: (Practical Pearl/Perle Pratique). African J Emerg Med 2012;2:127–8.
[28] Inoue S, Akazawa S, Fukuda H, Shimizu R. Another simple method for ring removal. Anesthesiology 1995;83:1133–4.
[29] Mullett ST. Ring removal from the oedematous finger. An alternative method. J Hand Surg [Br] 1995;20:49.
[30] Kapickis M, Kutz JE. Titanium alloy ring crush injury. Am J Emerg Med 2007;25:1084.e3–5.
[31] Allen KA, Rizzo M, Sadosty AT. A method for the removal of tungsten carbide rings. J Emerg Med 2012;43:93–6.
[32] Ricks R. Removal of a tungsten carbide wedding ring with a diamond tipped dental drill. J Plast Reconstr Aesthet Surg 2010;63:701–2.
[33] Shafiroff BB. Easy removal of a partially embedded ring from a finger. Plast Reconstr Surg 1979;63:841–2.
[34] Woodburn B. Ring removal. Can J Rural Med 2010;15:167.
[35] Brock S, Kuhn W. Removal of constricting bands using the Dremel drill. Acad Emerg Med 1999;6:1182–3.
[36] Greenspan L. Tourniquet syndrome caused by metallic bands: a new tool for removal. Ann Emerg Med 1982;11:375–8.
[37] Louw J, Hodsgon E. An unconventional ring removal tecnique for hard-to-remove rings. African journal of Emergency Medicine 2012;2:81–3.
[38] Bleibleh S, Childs J, Baqai N. Removal of a titanium alloy ring. Br J Hosp Med 2011;72:529.
[39] Fasano Jr FJ, Hansen RH. Foreign body granuloma and synovitis of the finger: a hazard of ring removal by the sawing technique. J Hand Surg [Am] 1987;12:621–3.
[40] Baker A, Rylance K, Giles S. The occasional ring removal. Can J Rural Med 2010;15:26–8.
[41] Rubman MH, Taylor K. A rapid method for emergency ring removal. Am J Orthop 1996;25:42–4.
[42] Zeng BW, Guo YJ, Huang CC. Embedded ring injury of the middle finger in an amphetamine abuser. J Chin Med Assoc 2006;69:95–7.
[43] Taylor SP, Boyd MJ. Unusually difficult ring removal from a finger solved using a dental instrument. Emerg Med Australas 2005;17:285–7.
[44] Chambers AF, Harper A. Removal of a titanium ring using a dental saw. J Plast Reconstr Aesthet Surg 2012;65:128–9.
[45] Sazwan RS, Anas AH, Nazer B, Hashairi F, Shaik Farid AW, Abu Yazid MN. The use of dental drill in removing entrapped finger by metal ring in emergency department. Med J Malaysia 2012;67:349–50.
[46] Palmer AK. Complications from tourniquet use. Hand Clin 1986;2:301–5.