The American Journal of Sports Medicine
http://ajs.sagepub.com/

Fresh Osteochondral Allograft Transplantation for Isolated Patellar Cartilage Injury

Guilherme C. Gracitelli, Gokhan Meric, Pamela A. Pulido, Simon Görtz, Allison J. De Young and William D. Bugbee

Am J Sports Med published online January 16, 2015
DOI: 10.1177/0363546514564144

The online version of this article can be found at:
http://ajs.sagepub.com/content/early/2015/01/16/0363546514564144

Published by:
SAGE
http://www.sagepublications.com

On behalf of:
American Orthopaedic Society for Sports Medicine
AOSSM

AJSM PreView, published on January 16, 2015 as doi:10.1177/0363546514564144

Fresh Osteochondral Allograft Transplantation for Isolated Patellar Cartilage Injury

Guilherme C. Gracitelli,*† MD, Gokhan Meric,*‡ MD, Pamela A. Pulido,* BSN, Simon Görtz,§‖ MD, Allison J. De Young,* MPA, PA-C, and William D. Bugbee,‖¶ MD
Investigation performed at the Shiley Center for Orthopaedic Research and Education and the Department of Orthopaedic Surgery, Scripps Clinic, La Jolla, California, USA

Background: The treatment of patellofemoral cartilage injuries can be challenging. Osteochondral allograft (OCA) transplantation has been used as a treatment option for a range of cartilage disorders.

Purpose: To evaluate functional outcomes and survivorship of the grafts among patients who underwent OCA for patellar cartilage injuries.

Study Design: Case series; Level of evidence, 4.

Methods: An institutional review board–approved OCA database was used to identify 27 patients (28 knees) who underwent isolated OCA transplantation of the patella between 1983 and 2010. All patients had a minimum 2-year follow-up. The mean age of the patients was 33.7 years (range, 14-64 years); 54% were female. Twenty-six (92.9%) knees had previous surgery (mean, 3.2 procedures; range, 1-10 procedures). The mean allograft area was 10.1 cm^2 (range, 4.0-18.0 cm^2). Patients returned for clinical evaluation or were contacted via telephone for follow-up. The number and type of reoperations were assessed. Any reoperation resulting in removal of the allograft was considered a failure of the OCA transplantation. Patients were evaluated pre- and postoperatively using the modified Merle d'Aubigné-Postel (18-point) scale, the International Knee Documentation Committee (IKDC) pain, function, and total scores, and the Knee Society function (KS-F) score. Patient satisfaction was assessed at latest follow-up.

Results: Seventeen of the 28 knees (60.7%) had further surgery after the OCA transplantation; 8 of the 28 knees (28.6%) were considered OCA failures (4 conversions to total knee arthroplasty, 2 conversions to patellofemoral knee arthroplasty, 1 revision OCA, 1 patellectomy). Patellar allografting survivorship was 78.1% at 5 and 10 years and 55.8% at 15 years. Among the 20 knees (71.4%) with grafts in situ, the mean follow-up duration was 9.7 years (range, 1.8-30.1 years). Pain and function improved from the preoperative visit to latest follow-up, and 89% of patients were extremely satisfied or satisfied with the results of the OCA transplantation.

Conclusion: OCA transplantation was successful as a salvage treatment procedure for cartilage injuries of the patella.

Keywords: patella; cartilage; osteochondral allograft; osteochondral defect; osteochondral transplantation

Cartilage lesions of the patella are common and are described in up to 36% of patients undergoing arthroscopic surgery.[7] Large and complex lesions of the patella are a potentially debilitating problem and present a difficult clinical challenge. If untreated, lesions worsen over time and may progress to arthritis.[9]

Several treatment algorithms have been reported in the current literature for patellar cartilage injuries.[1,3,11,13,17,30,31] Nonoperative treatment can relieve symptoms but theoretically cannot prevent cartilage degeneration.[19,35] Some inherent difficulties involved with patellar cartilage injury repairs are joint instability, complex anatomy of the patellofemoral joint, and high joint reaction forces.[2,19,22] Previous studies of osteochondral allograft (OCA) transplantation in the patella are small case series with short follow-up times.[12,37] Further studies are needed to clarify the indications and the results of osteochondral allograft transplantation in the patella.[1,3,11,13,17,30,31]

We present a cohort with at least 2 years of follow-up to analyze the outcome of OCA transplantation performed in patellar osteochondral injuries.

MATERIALS AND METHODS

With institutional review board approval, 27 patients (28 knees) who had undergone an isolated osteochondral allograft transplantation of the patella between 1983 and 2010 were identified from our institution's OCA database. All patients had a minimum follow-up of 2 years. Patients who underwent OCA transplantation during the same

The American Journal of Sports Medicine, Vol. XX, No. X
DOI: 10.1177/0363546514564144

timeframe in the patella combined with any other portion of the knee including the trochlea (25 knees), femoral condyle (24 knees), tibial plateau (3 knees), or combination of those locations (12 knees) were excluded.

Preoperatively, donor and recipient were matched using standard anteroposterior and lateral radiographs of the recipient corrected for magnification. Preoperatively no immunosuppressive therapy was used.[5] Fresh donor tissue was obtained from the American Association of Tissue Banks. Donor tissue was recovered within 24 hours of donor death and then stored at 4°C and was used within 5 and 21 days of donor death.[29]

The indications of this surgery were isolated patellar lesions with International Cartilage Repair Society (ICRS) grades 3 and 4, patients who had failed previous surgical and nonsurgical interventions, and/or patients who wished to avoid prosthetic arthroplasty. The majority of the procedures utilized a standard midline incision followed by eversion of the patella. The location and size of the lesion were detected. These characteristics determined whether a partial or total type patellar graft was used. For small-sized (<5 cm^2) and medium-sized (5-10 cm^2) lesions, a dowel technique was used (Figure 1). Total patellar allograft (Shell technique) was used for lesions larger than 10 cm^2 or if the lesion comprised more than 75% of the patella. For the dowel technique, the margins of the cartilage lesion were determined utilizing 15 to 35 mm cylindrical templates, and a guide wire was driven into the center of the templates. The cylindrical reamer was used to remove the diseased cartilage until normal bleeding subchondral bone was encountered. After debridement, the graft area was prepared down to a depth of 5 to 10 mm. Osseous grafts were harvested from identical patellar locations on the donor cartilage using a coring reamer. To decrease immunogenicity, osseous grafts received pulsatile lavage with saline to remove potentially immunogenic marrow elements. Usually, fixation of the graft was achieved by press-fit, but for the total patellar graft, we supplemented fixation using compression screws and/or absorbable internal fixation devices where indicated (Chondral Dart; Arthrex) (Figure 2). We performed concomitant osteotomies when there was significant malalignment or instability of the patellofemoral joint noted in the physical examination. We did not base the surgical indication on purely quantitative measurement of alignment, and we did not employ tibial tubercle osteotomies solely to unload the patellofemoral joint.

Postoperatively, patients were allowed weightbearing as tolerated with the knee locked in extension and limiting range of motion to 30° to avoid the patella engaging the trochlea. Closed-chain exercises were initiated at 4 weeks postoperatively. Braces were discontinued once the patient had adequate quadriceps control and could perform a straight-leg raise without an extension lag. Patients were allowed to return to recreational and sports activities after 6 months but were advised to avoid high-loading activities until 6 to 12 months postoperatively.[5] All patients were followed radiographically until graft healing was demonstrated (Figure 3, A and B), and for some symptomatic patients, magnetic resonance imaging was acquired (Figure 4).

Available patients were examined in the clinic to measure current pain levels, joint function, and satisfaction with the procedure or the patients were contacted by telephone if unable to return for follow-up in the clinic. Of the 20 patients whose grafts were still in situ, 3 (15%) returned to the clinic for follow-up, and 17 (85%) were contacted via telephone and/or mail. Reoperation data were followed up solely by telephone. Clinical scores were obtained by mailed questionnaires. Preoperative and postoperative pain and function were evaluated using the modified Merle d'Aubigné-Postel (18-point) score[8,15]; the International Knee Documentation Committee (IKDC) pain, function, and total scores[24]; and the Knee Society function (KS-F) score.[23] Overall satisfaction with the allograft surgery was also determined using a 5-point scale with descriptors from extremely satisfied to extremely dissatisfied. All questionnaires and surveys were administered preoperatively and at final follow-up. The number and type of further surgeries on the operative joint were captured. Any reoperation resulting in removal of the allograft was considered a failure of the OCA transplantation.

Means and frequencies were calculated to describe demographic data, details regarding the allograft, number and type of further surgeries after the OCA transplantation, and patient satisfaction at latest follow-up. The Kaplan-Meier method was used to calculate allograft survivorship with graft failure (revision of the graft or conversion to arthroplasty) as the endpoint. The Wilcoxon signed-rank test was used to assess change from preoperative to latest follow-up on the modified Merle d'Aubigné-Postel score; IKDC pain, function, and total scores; and KS-F score. A P value of .05 was used to determine statistical significance. SPSS version 13.0 was used for all analyses (IBM Corp).

RESULTS

Patients' demographic data (age, sex, body mass index, diagnosis, and number of previous surgeries) and allograft details were recorded (Table 1). Seven patients had

¶Address correspondence to William D. Bugbee, MD, Scripps Clinic, 10666 North Torrey Pines Road, MS 116, La Jolla, CA 92037, USA (e-mail: Bugbee.william@scrippshealth.org).

*Shiley Center for Orthopaedic Research and Education, Scripps Clinic, La Jolla, California, USA.

†Department of Orthopaedic Surgery, Federal University of São Paulo, Brazil.

‡Department of Orthopaedic Surgery, Balikesir University, Balikesir, Turkey.

§Department of Orthopaedic Surgery, University of California, San Diego School of Medicine, La Jolla, California, USA.

‖Department of Orthopaedic Surgery, Scripps Clinic, La Jolla, California, USA.

One or more of the authors has declared the following potential conflict of interest or source of funding: W.D.B. is a consultant for and has received research support from the Joint Restoration Foundation, a nonprofit tissue bank that receives, processes, and distributes osteochondral allografts. G.M. was supported by Balikesir University Scientific Research Projects Unit–Balikesir/Turkey (Ref No. 14/02-001). G.C.G. was supported by Coordination for the Improvement of Higher Education Personnel (CAPES), Brazil.

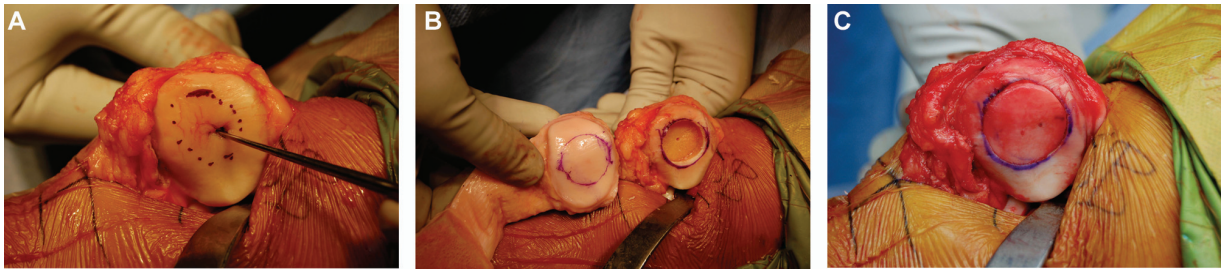

Figure 1. Intraoperative images of a patellar lesion amenable to plug the allograft. (A) Patella with osteochondral lesion. Note the probe inside the subchondral cyst. (B) Patellar lesion has been prepared, and homologous site on patellar allograft is marked for harvest. (C) Allograft plug in place; no additional fixation was used.

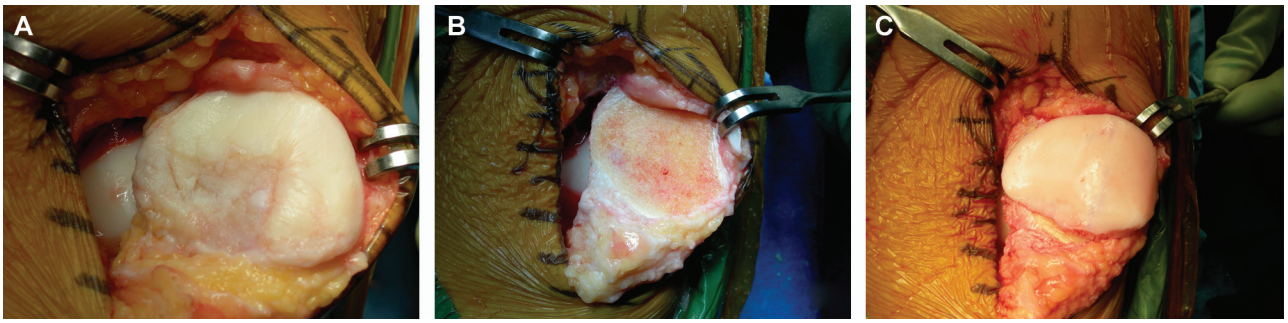

Figure 2. Total patellar osteochondral allograft transplantation. (A) A large patellar chondral lesion. The entire chondral surface demonstrated severe softening. (B) Patellar resection completed. (C) Patellar allograft in place and fixed with 2 small lag screws from the anterior surface.

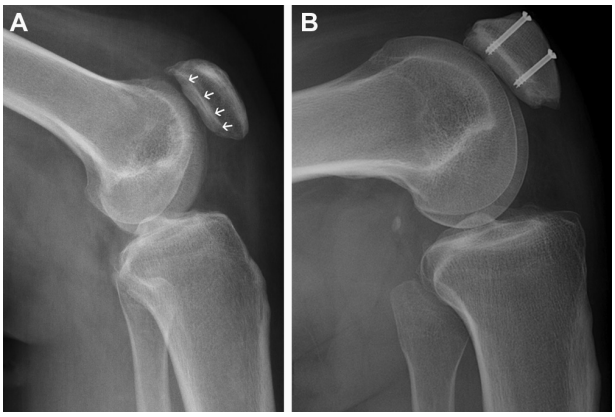

Figure 3. Postoperative lateral radiograph after osteochondral allograft (OCA) transplantation. (A) A partial allograft with press-fit fixation using dowel technique. Arrows show the limits of the allograft. (B) A total OCA transplantation fixed with 2 cannulated screws using the Shell technique.

concomitant lateral release, 3 patients had realignment surgery for the extensor mechanism (1 vastus medialis imbrication, 1 tibial tubercle osteotomy with medial patellofemoral ligament reconstruction, 3 tibial tubercle osteotomies isolated). The major indication for OCA included degenerative chondral lesions in 15 patients (53.6%) (Table 1).

Isolated patellar allograft transplantation survivorship was 78.1% at 5 and 10 years and was 55.8% at 15 years.

Figure 4. Sagittal intermediate-weighted magnetic resonance image of a patient after osteochondral allograft (OCA) transplantation in the patella. The OCA cartilage surface congruity is normal compared with adjacent host cartilage. Subchondral bone marrow signal is preserved, and the host-graft junction demonstrates osseous incorporation.

TABLE 1
Patient Demographics and Allograft Details (N = 28 knees)

Age, y, mean (range)	33.7 (14-64)
Sex, n (%)	
Male	13 (46.4)
Female	15 (53.6)
Body mass index, mean (range)	27.1 (19.4-42.1)
Diagnosis, n (%)	
Osteochondritis dissecans	1 (3.6)
Degenerative chondral lesion	15 (53.6)
Traumatic chondral injury	4 (14.3)
Osteoarthritis	2 (7.1)
Osteochondral fractures	5 (17.9)
Avascular necrosis	1 (3.6)
Previous surgery on operative joint	26 (92.9)
Types of previous surgeries, n (%)	
Chondroplasty	7 (26.9)
Chondroplasty and extensor mechanism surgery	5 (19.2)
Microfracture and extensor mechanism surgery	3 (11.6)
Loose body removal	3 (11.6)
Meniscectomy	2 (7.7)
Femoral osteotomy	2 (7.7)
Bone graft	1 (3.8)
Osteochondral autograft transplant	1 (3.8)
Allograft transplantation	1 (3.8)
Periosteum implant	1 (3.8)
Number of grafts, n (%)	
1	26 (92.9)
2	2 (7.1)
Total graft area, cm^2, mean (range)	10.1 (4-18)

TABLE 2
Reoperations After Osteochondral Allograft (OCA) Transplantation[a]

Procedure	n
Reoperations	
Arthroscopic debridement	9
Hardware removal	6
Anterior cruciate ligament reconstruction	1
Patellofemoral realignment	1
Manipulation	1
Loose body removal	1
OCA failures	
Converted to total or partial arthroplasty	6
Patellectomy after traumatic fall	1
OCA revision	1

[a]Some knees had >1 reoperation.

Seventeen of the 28 knees (60.7%) had further surgery after the OCA transplantation (Table 2). Eight of the 28 knees (28.6%) were considered OCA failures (4 conversions to total knee arthroplasty [TKA], 2 conversions to patellofemoral knee arthroplasty, 1 revision OCA, 1 patellectomy). Patients were converted to TKA at a mean of 22.8 months, converted to patellofemoral arthroplasty at a mean of 12.3 months, underwent patellectomy at 9 months, and required a revision of OCA at 14 months postoperatively.

TABLE 3
Preoperative and Postoperative Pain and Function Among Patients With Grafts in Situ at Latest Follow-up (n = 20)[a]

Measure	Preoperative	Postoperative	*P* Value
Modified d'Aubigné-Postel			.003
score, mean	12.0	15.2	
% Excellent	—	22.2	
% Good	5.3	55.6	
% Fair	63.2	5.6	
% Poor	31.6	16.7	
IKDC score, mean			
Pain	6.2	3.4	.002
Function	3.5	7.0	.001
Total	36.5	66.5	.003
KS-F score, mean	64.6	80.5	.003

[a]The Modified d'Aubigné-Postel (18-point) score is graded as follows: 18 = excellent, 15-17 = good, 12-14 = fair, <12 = poor. IKDC, International Knee Documentation Committee; KS-F, Knee Society function.

Twenty of the 28 knees (71.4%) had the allograft in situ at latest follow-up; the mean follow-up duration of these 20 knees was 9.7 ± 7.5 years. Scores on the IKDC, modified Merle d'Aubigné-Postel, and KS-F improved significantly from the preoperative visit to latest follow-up (Table 3). Seventy-seven percent of knees showed excellent or good results according to the modified Merle d'Aubigné-Postel score categories. Eighty-nine percent of patients were extremely satisfied or satisfied with the results of the OCA transplantation.

DISCUSSION

In this study, overall survival of the patellar allograft was 78.1% at 5 and 10 years. Eight knees (28.6%) were considered to have allograft failure. Patients who retained their grafts in situ had significant improvement in pain and knee function postoperatively, although 9 (45%) patients required further surgeries.

Previous studies[4,5,20] of femoral condyle allografts showed overall allograft survival rates ranging from 84.5% to 95% at 5 years. Levy et al[28] reported 82% and 74% survivorship at 10 years and 15 years, respectively, in 122 patient (129 knees) who underwent OCA transplantation of the femoral condyle. Emmerson et al[10] treated 66 knees in 64 patients with OCA for osteochondritis dissecans, and 47 (72%) knees showed good and excellent results at a mean 7.7 years of follow-up.

Few studies have reported the outcome of OCA transplantation of the patella. Torga Spack et al[37] reported 14 patellofemoral osteochondral allografts were implanted in 11 patients for patellofemoral arthritis. At last follow-up (average, 10 years; range, 2.5-17.5 years), 8 grafts were in place. All the surviving allografts in this study were to treat reciprocal lesions of the trochlea and patella, considered bipolar grafts. The only 2 isolated patellar allografts failed, after 13

months and 72 months postoperatively, because of fragmentation and instability, respectively. Chu et al[6] reported 55 patients who were treated with osteochondral allografts. Overall analysis reported 45 (76%) knees with good or excellent results. Five isolated patellar allografts of this group survived with no failure at last follow-up, and all 5 patients rated their results as good to excellent. Jamali et al[25] analyzed 20 knees of 18 patients who were treated with fresh osteochondral allografts. Twelve knees were treated with bipolar allografts; 8 knees were treated with isolated patellar allografts, of which 2 failed. In their series, good or excellent results were reported in 60% of patients at a mean follow-up of 94 months. All studies reported were small case series with short follow-up. Our series is the largest reported series of patellar allografts with long-term follow-up.

Other treatment alternatives for osteochondral lesions of the patella are microfracture, autologous osteochondral transplantation (OAT), autologous chondrocyte implantation (ACI), and patellofemoral arthroplasty (PFA), which have been widely investigated. In a systematic review, Noyes and Barber-Westin[33] reported a high rate of failure or a low function in 22% after PFA, 53% after OCA, and a range from 8% to 60% after ACI. Gomoll et al[18] reported the largest multicenter cohort of 110 patients with at least 4 years of follow-up after ACI for patellar lesions with significant improvement in function scores and self-rated criteria. Only 8% of patellar ACI treatment failed, but residual disability was detected in the final functional scores. Filardo et al[14] recently reported a prospective study of 49 patients with patellofemoral chondral lesions of the knee who were treated with matrix-assisted autologous chondrocyte transplantation (MACT) and followed for a minimum of 5 years. Significant improvement in all scores was observed after treatment. Patellar lesions required more realignment procedures. The comparative analysis showed better results for trochlear lesions compared with patellar lesions.

Microfracture is a technique that is available worldwide for treating chondral injuries in the knee, but without promising results. Solheim et al[36] reported 110 patients treated with microfracture; 10 of these patients had isolated patellar lesions, and their failure rate was 18% at a median 5 years' follow-up. Microfracture in knee compartments other than the femoral condyle has been shown to deteriorate after a mean of 18 to 36 months.[27]

The role of the OAT technique in treating patellar chondral defects is controversial. In the literature, the patellar OAT procedure presents a wide range of clinical results. Figueroa et al[12] treated 10 patients' isolated patellar cartilage lesions with osteochondral autografts. The Lysholm score improved from 73.8 ± 8.36 to 95 ± 4.47 at a mean follow-up of 37.3 months, and all patients reported good or excellent results. Bentley et al[3] reported failure in all of 5 patients with patellar cartilage lesions who were treated with OAT procedures. Nho et al[32] treated 22 patients with patellar autograft, and 9 patients underwent concomitant distal realignment osteotomy. They found that the mean baseline scores for the isolated patellar allograft group were lower compared with those of the group that had simultaneous distal realignment, but the difference was not significant. Convexity of the patellar surface and thickness of patellar cartilage are considered difficult to perfectly match with the autograft obtained, which may cause some step-off and result in a cyst formation.[19,39]

Patellofemoral arthroplasty is another treatment alternative for advanced patellofemoral cartilage injuries. Success rates for this procedure have been reported as 55% to 75% at long-term follow-up.[26,38] Van Jonbergen et al[38] treated 85 knees with PFA. They reported a failure rate of 24% at a mean follow-up of 13.3 years. They concluded extensor malalignment, malposition, and type of the prosthesis were correlated with failure. Kooijman et al[26] performed PFA on 51 patients (56 knees) whose average age was 50 years and who were followed a mean of 17 years postoperatively. Twenty-five PFA patients needed reoperation, 10 knees of these required total knee arthroplasty, 2 knees underwent high tibial osteotomy, 7 knees had revision PFA, and others had minor procedures.

Inferior results of patella OCA compared with femoral condyle OCA may be related to anatomic considerations. Even in spite of correction of cartilage disease and malalignment, residual dysplasia and functional defects of the limb or knee may affect overall outcome. Additionally, these factors may predispose the cartilage repair to failure.[22] Autologous chondrocyte studies previously advised aggressive correction of patellar maltracking and unloading of patellofemoral joint with anteromedialization tibial tubercle osteotomy, which resulted in better outcomes with a success rate from 70% to 80%, similar to those for femoral condyle ACI repair.[16,21,31,34] We did not routinely perform tibial tubercle osteotomy to unload the allograft. This may be a significant difference between OCA and ACI in the patellofemoral joint, as OCA is a fully formed structural graft that tolerates load after the graft integration. We only employed osteotomies when there was significant malalignment and instability of the patellofemoral joint; indeed, we do not believe that isolated osteotomy to unload the joint is necessary for osteochondral allograft in the patellofemoral joint. Our cohort included 8 patients with previous extensor realignment. Three concurrent realignment procedures were performed to correct extensor alignment.

As with all clinical investigations, we appreciate a number of methodological shortcomings that could threaten the validity of our conclusions. The patient cohort is small (28 knees). Another limitation of our study is the lack of a control group. The lack of long-term radiographic follow-up is also a weakness of the study; many patients travel long distances for treatment, and therefore routine check-ups were difficult to schedule. Telephone interviews or mailings for outcome scores provided information on basic outcome measures including graft survival, reoperation, pain, and function. We used the modified Merle d'Aubigné-Postel (18-point) scale, but this scoring system has not been validated in the knee. This scoring system is a simple, standardized method of retrospectively evaluating patient outcomes on an objective basis and is used commonly in the orthopaedic literature. Another limitation of the present study is due to lack of a good salvage treatment option for young patients regarding patellofemoral arthritis. Young patients may have to live with patellofemoral arthritis, increasing the survivorship rate. However, these patients have lower

clinical outcomes, which are represented by the lower functional outcomes in this study. Prospective studies also may give results that are more beneficial.

Our study is the largest reported series of OCA transplantation limited to the patella with long-term follow-up. The treatment of patellar cartilage injuries remains a difficult clinical challenge regardless of the surgical intervention chosen, with relatively high reoperation and revision rates. OCA transplantation was successful in the majority of this challenging cohort requiring major patellar resurfacing. We conclude that patellar allografting is a useful salvage treatment option for patellar cartilage injuries.

REFERENCES

1. Ackroyd CE, Chir B. Development and early results of a new patellofemoral arthroplasty. *Clin Orthop Relat Res*. 2005;436:7-13.
2. Beck PR, Thomas AL, Farr J, Lewis PB, Cole BJ. Trochlear contact pressures after anteromedialization of the tibial tubercle. *Am J Sports Med*. 2005;33:1710-1715.
3. Bentley G, Biant LC, Carrington RW, et al. A prospective, randomised comparison of autologous chondrocyte implantation versus mosaicplasty for osteochondral defects in the knee. *J Bone Joint Surg Br*. 2003;85:223-230.
4. Bugbee W, Cavallo M, Giannini S. Osteochondral allograft transplantation in the knee. *J Knee Surg*. 2012;25:109-116.
5. Bugbee WD. Fresh osteochondral allografts. *J Knee Surg*. 2002;15:191-195.
6. Chu CR, Convery FR, Akeson WH, Meyers M, Amiel D. Articular cartilage transplantation. Clinical results in the knee. *Clin Orthop Relat Res*. 1999;360:159-168.
7. Curl WW, Krome J, Gordon ES, Rushing J, Smith BP, Poehling GG. Cartilage injuries: a review of 31,516 knee arthroscopies. *Arthroscopy*. 1997;13:456-460.
8. Davidson PA, Rivenburgh DW, Dawson PE, Rozin R. Clinical, histologic, and radiographic outcomes of distal femoral resurfacing with hypothermically stored osteoarticular allografts. *Am J Sports Med*. 2007;35:1082-1090.
9. Davies-Tuck ML, Wluka AE, Wang Y, et al. The natural history of cartilage defects in people with knee osteoarthritis. *Osteoarthritis Cartilage*. 2008;16:337-342.
10. Emmerson BC, Gortz S, Jamali AA, Chung C, Amiel D, Bugbee WD. Fresh osteochondral allografting in the treatment of osteochondritis dissecans of the femoral condyle. *Am J Sports Med*. 2007;35:907-914.
11. Farr J. Autologous chondrocyte implantation improves patellofemoral cartilage treatment outcomes. *Clin Orthop Relat Res*. 2007;463:187-194.
12. Figueroa D, Melean P, Calvo R, Gili F, Zilleruelo N, Vaisman A. Osteochondral autografts in full thickness patella cartilage lesions. *Knee*. 2011;18:220-223.
13. Filardo G, Kon E, Andriolo L, Di Martino A, Zaffagnini S, Marcacci M. Treatment of ''patellofemoral'' cartilage lesions with matrix-assisted autologous chondrocyte transplantation: a comparison of patellar and trochlear lesions. *Am J Sports Med*. 2014;42:626-634.
14. Filardo G, Kon E, Di Martino A, Iacono F, Marcacci M. Arthroscopic second-generation autologous chondrocyte implantation: a prospective 7-year follow-up study. *Am J Sports Med*. 2011;39:2153-2160.
15. Garrett JC. Fresh osteochondral allografts for treatment of articular defects in osteochondritis dissecans of the lateral femoral condyle in adults. *Clin Orthop Relat Res*. 1994;303:33-37.
16. Gigante A, Enea D, Greco F, et al. Distal realignment and patellar autologous chondrocyte implantation: mid-term results in a selected population. *Knee Surg Sports Traumatol Arthrosc*. 2009;17:2-10.
17. Gillogly SD, Arnold RM. Autologous chondrocyte implantation and anteromedialization for isolated patellar articular cartilage lesions: 5- to 11-year follow-up. *Am J Sports Med*. 2014;42(4):912-920.
18. Gomoll AH, Gillogly SD, Cole BJ, et al. Autologous chondrocyte implantation in the patella: a multicenter experience. *Am J Sports Med*. 2014;42:1074-1081.
19. Gomoll AH, Minas T, Farr J, Cole BJ. Treatment of chondral defects in the patellofemoral joint. *J Knee Surg*. 2006;19:285-295.
20. Gortz S, De Young AJ, Bugbee WD. Fresh osteochondral allografting for steroid-associated osteonecrosis of the femoral condyles. *Clin Orthop Relat Res*. 2010;468:1269-1278.
21. Henderson IJ, Tuy B, Connell D, Oakes B, Hettwer WH. Prospective clinical study of autologous chondrocyte implantation and correlation with MRI at three and 12 months. *J Bone Joint Surg Br*. 2003;85:1060-1066.
22. Hungerford DS, Barry M. Biomechanics of the patellofemoral joint. *Clin Orthop Relat Res*. 1979;144:9-15.
23. Insall J, Tria AJ, Scott WN. The total condylar knee prosthesis: the first 5 years. *Clin Orthop Relat Res*. 1979;145:68-77.
24. Irrgang JJ, Anderson AF, Boland AL, et al. Development and validation of the international knee documentation committee subjective knee form. *Am J Sports Med*. 2001;29:600-613.
25. Jamali AA, Emmerson BC, Chung C, Convery FR, Bugbee WD. Fresh osteochondral allografts: results in the patellofemoral joint. *Clin Orthop Relat Res*. 2005;437:176-185.
26. Kooijman HJ, Driessen AP, van Horn JR. Long-term results of patellofemoral arthroplasty. A report of 56 arthroplasties with 17 years of follow-up. *J Bone Joint Surg Br*. 2003;85:836-840.
27. Kreuz PC, Steinwachs MR, Erggelet C, et al. Results after microfracture of full-thickness chondral defects in different compartments in the knee. *Osteoarthritis Cartilage*. 2006;14:1119-1125.
28. Levy YD, Gortz S, Pulido PA, McCauley JC, Bugbee WD. Do fresh osteochondral allografts successfully treat femoral condyle lesions? *Clin Orthop Relat Res*. 2013;471:231-237.
29. McAllister DR, Joyce MJ, Mann BJ, Vangsness CT Jr. Allograft update: the current status of tissue regulation, procurement, processing, and sterilization. *Am J Sports Med*. 2007;35:2148-2158.
30. McGinley BJ, Cushner FD, Scott WN. Debridement arthroscopy. 10-year followup. *Clin Orthop Relat Res*. 1999;367:190-194.
31. Minas T, Bryant T. The role of autologous chondrocyte implantation in the patellofemoral joint. *Clin Orthop Relat Res*. 2005;436:30-39.
32. Nho SJ, Foo LF, Green DM, et al. Magnetic resonance imaging and clinical evaluation of patellar resurfacing with press-fit osteochondral autograft plugs. *Am J Sports Med*. 2008;36:1101-1109.
33. Noyes FR, Barber-Westin SD. Advanced patellofemoral cartilage lesions in patients younger than 50 years of age: is there an ideal operative option? *Arthroscopy*. 2013;29:1423-1436.
34. Pascual-Garrido C, Slabaugh MA, L'Heureux DR, Friel NA, Cole BJ. Recommendations and treatment outcomes for patellofemoral articular cartilage defects with autologous chondrocyte implantation: prospective evaluation at average 4-year follow-up. *Am J Sports Med*. 2009;37(suppl 1):33s-41s.
35. Post WR. Anterior knee pain: diagnosis and treatment. *J Am Acad Orthop Surg*. 2005;13:534-543.
36. Solheim E, Oyen J, Hegna J, Austgulen OK, Harlem T, Strand T. Microfracture treatment of single or multiple articular cartilage defects of the knee: a 5-year median follow-up of 110 patients. *Knee Surg Sports Traumatol Arthrosc*.2010;18:504-508.
37. Torga Spak R, Teitge RA. Fresh osteochondral allografts for patellofemoral arthritis: long-term followup. *Clin Orthop Relat Res*. 2006;444:193-200.
38. van Jonbergen HP, Werkman DM, Barnaart LF, van Kampen A. Long-term outcomes of patellofemoral arthroplasty. *J Arthroplasty*. 2010;25:1066-1071.
39. von Rechenberg B, Akens MK, Nadler D, et al. Changes in subchondral bone in cartilage resurfacing—an experimental study in sheep using different types of osteochondral grafts. *Osteoarthritis Cartilage*. 2003;11:265-277.